



## Micropapillary carcinoma in a dog: case report

[*Carcinoma micropapilar em cão: relato de caso*]

### "Case Report/Relato de Caso"

Cristhian Rene Vargas **Estrada**<sup>1</sup>, Bruna Fernanda **Firmo**<sup>1</sup>, Marjury Cristina **Maronezi**<sup>1</sup>, André de Mattos **Faro**<sup>1</sup>, Daniele Belchior **Vela**<sup>1</sup>, Mariana Palma Correa da **Silva**<sup>1</sup>, Tryssia Scalon Magalhães **Moi**<sup>1</sup>, Brenda Mendonça de **Alcântara**<sup>1</sup>, Letícia **Bonato**<sup>1</sup>, Rafael Ricardo **Huppés**<sup>2</sup>, Andriago Barboza **De Nardi**<sup>1</sup>

<sup>1</sup>Universidade Estadual Paulista, Campus de Jaboticabal, Jaboticabal-UF, Brasil.

<sup>2</sup>Clínica Veterinária UNIVET, São José Rio Preto-SP, Brasil.

\*Corresponding autor/autor para correspondência: E-mail: [crisvaresmvz@gmail.com](mailto:crisvaresmvz@gmail.com)

#### Abstract

Mammary neoplasms in female dogs have a high incidence. Among the several histological types observed, micropapillary carcinoma is considered one of the most aggressive due to vascular invasion, metastases, and short survival time. The present objective was to describe a case of mammary gland micropapillary carcinoma, with cutaneous metastasis, in a dog. A 14-year-old intact nulliparous mixed-breed bitch, weighing 8kg, with a history of pseudocyesis and no history of contraceptive administration, presented to the Veterinary Reproduction and Obstetrics Service from "Governador Laudo Natel" Hospital, FCAV, UNESP, Jaboticabal, with an ulcerated nodule in the mammary gland for approximately one month. After stabilization of clinical parameters and preoperative exams, a radical unilateral mastectomy and ipsilateral axillary and inguinal lymphadenectomy were performed. Histopathology revealed micropapillary carcinoma with clear surgical margins, however, there were metastases in both lymph nodes. Antineoplastic chemotherapy was refused by the owners. On the 60th day after surgery, there was an inflammatory reaction in the surgical scar region, with a small cutaneous ulceration, where elastography showed rigidity and shear velocity of 7.84m/s. Skin biopsy revealed metastasis of the micropapillary carcinoma. Even with continued treatment since the patient was first examined, the ulcerations progressed, compromising the animal's welfare and physiological activities, and on the 110th day after surgery, euthanasia was decided on. A correct diagnosis and knowledge of tumor biological behavior are important points for choosing the correct treatment. Acoustic Radiation Force Image (ARFI) elastography has been shown to be a fast and non-invasive diagnostic method for detection of recurrent micropapillary carcinoma.

**Keywords:** elastography; lymphadenectomy; mastectomy; oncology.

#### Resumo

As neoplasias mamárias em cadelas apresentam alta incidência. Vários tipos histológicos são observados, dentre eles, o carcinoma micropapilar é considerado um dos mais agressivos por ter relação com invasão vascular, metástases e baixo tempo de sobrevivência. Objetivou-se descrever um caso de carcinoma micropapilar mamário, com metástase cutânea, em uma cadela. Uma canina, fêmea, 14 anos, 8 kg, não castrada, nulípara, com histórico de pseudociese e sem histórico de medicações contraceptivas, foi atendida pelo Serviço de Reprodução e Obstetrícia Veterinária do "Hospital Governador Laudo Natel", FCAV, UNESP, Jaboticabal, apresentando nodulação mamária ulcerada há aproximadamente 1 mês. Após estabilização e realização de exames prévios, realizou-se mastectomia unilateral radical associada à linfadenectomia axilar e inguinal ipsilateral. O exame histopatológico foi compatível com carcinoma micropapilar, com margens cirúrgicas livres, porém, presença de metástase nos linfonodos. Os tutores optaram por não realizar quimioterapia. Após 60 dias do pós-operatório, paciente retornou apresentando inflamação na cicatriz cirúrgica, com pequenas ulcerações cutâneas, onde o elastograma revelou rigidez e velocidade média de cisalhamento de

Received 28 August 2019. Accepted 14 May 2021.

DOI: <https://doi.org/10.26605/medvet-v15n3-2704>

7,84m/s. A biópsia cutânea das regiões acometidas evidenciou metástase do carcinoma micropapilar. As ulcerações progrediram, comprometendo o bem-estar do animal e suas atividades fisiológicas, quando aos 110 dias pós-operatório, optou-se pela eutanásia. O diagnóstico preciso e o conhecimento do comportamento biológico da neoplasia são essenciais para o correto tratamento, podendo a terapia antineoplásica influenciar no tempo de sobrevivência do animal. A elastografia de “Acoustic Radiation Force Image” (ARFI) demonstrou ser um método de diagnóstico rápido e não invasivo para detecção de recidiva de carcinoma micropapilar.

**Palavras-chaves:** elastografia; linfadenectomia; mastectomia; oncologia.

## Introduction

Mammary neoplasms in dogs have great importance in veterinary practice due to their similarity with mammary gland cancer in women. The incidence of mammary tumors represents 52% of all neoplasms that affect female dogs, approximately 50% of which have malignant characteristics (Feliciano et al., 2012). Due to the high malignancy rate of this neoplasm, the main cause of death is related to a high metastasis rate, mainly in regional lymph nodes and pulmonary tissues. In addition, neoplastic cell dispersion to other tissues, such as kidneys, liver, spleen, and brain can also occur less frequently (Franzoni et al., 2017).

Ultrasonography (US) is an important method for detecting metastasis in abdominal organs and regional lymph nodes (Silva et al., 2018). Mammary gland US enables characterization of the lesion and follow-up of eventual recurrences, however, US is not adequate to differentiate malignancy of lesions (Feliciano et al., 2008). Acoustic Radiation Force Image (ARFI) elastography is a promising diagnostic imaging technique that allows accurate identification of malignant lesions in the mammary gland, in dogs and women, with a non-invasive method (Ricci et al., 2014; Feliciano et al., 2018).

Neoplasms may have different histological subtypes. Therefore, histopathologic classification and histological staging of the neoplasm are necessary to recognize its behavior (Cassali et al., 2011). Micropapillary carcinoma is a special subtype of invasive mammary gland carcinoma which manifests in female dogs. Because of its characteristics of being a highly malignant and aggressive cancer, with extensive invasion and metastasis in regional lymph nodes, prognosis is unfavorable, and the mean survival time is 120 days in bitches (Marchió et al., 2008; Gamba et al., 2013; Tang et al., 2017).

The objective of the present study is to report a case of mammary micropapillary carcinoma and cutaneous metastasis in a bitch.

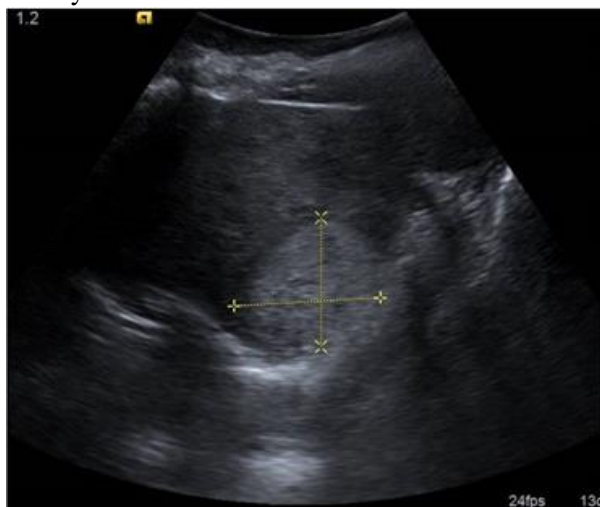
## Case Report

A 14-year-old intact nulliparous mixed-breed bitch, weighing 8kg, with pseudocyesis and no history of oral or injectable contraceptive use presented to the Veterinary Reproduction and Obstetrics Service of the “Governador Laudo Natel” Hospital, FCAV, UNESP, Jaboticabal. The patient had an ulcerated nodule with hemorrhagic secretion and an estimated evolution of one month.

On physical examination, the patient had a good general condition, normal physiological parameters for the species, signs of general inflammation of the mammary glands, and milk secretion. The presence of a single ulcerated nodule was observed in the mammary gland, between the right caudal abdominal and right inguinal mammary glands (M4-M5). Adequate measurement of the nodule was not possible due to inflammation of the mammary gland.

Complementary exams were performed, including complete blood count, which showed leukocytosis. Serum biochemistry (alanine aminotransferase, creatinine, urea) was within normal limits. Electrocardiogram, urinalysis and protein-creatinine ratio (UP:UC) did not show any considerable changes. Thoracic radiographs did not show any visible pulmonary metastasis, and abdominal ultrasound revealed the presence of a solid hyperechogenic mass, with defined contours, measuring 3.19 cm x 1.78 cm, without vascularization on color Doppler (Figure 1), located on the medial region of the right hepatic lobe. Treatment for pseudocyesis was initiated with administration of cabergoline, at a dosage of 0.05 mg/kg, orally, every 24h, for 10 days, antimicrobial therapy with cephalexin, 30 mg/kg, orally, every 24h, for 10 days, and ranitidine, 2 mg/kg, orally, every 24h, for 10 days. A cold

compress was performed every 8 hours, throughout the area of the mammary glands, the region was cleaned with saline solution 0.9%, and rifamycin was applied over the ulcerated region, twice daily, and Elizabethan collar was used for 10 days.



**Figure 1.** Hyperechoic nodular structure in the liver in a dog with micropapillary carcinoma (between the cursors).

After 10 days of treatment, the patient returned for reassessment. On physical examination, edema was considerably reduced, allowing measurement of the nodule between M4 and M5 (5.2 cm x 4.5 cm x 2.7 cm), and there was slight presence of milk secretion. There was no longer inflammation or milky secretion in the contralateral mammary gland. Aiming for complete resolution, treatment was continued for seven additional days. Subsequently, all blood tests were repeated, and the surgery was planned.

Right unilateral mastectomy, with ipsilateral axillary and inguinal lymphadenectomy, and ovariohysterectomy (Figure 2) were performed. The post-surgical systemic treatment protocol was based on cephalexin 30mg/kg, B.I.D., ranitidine 2mg/kg, B.I.D., tramadol hydrochloride 3mg/kg, T.I.D., all orally, for 10 days. Prescribed topical care included cleaning with 0.9% saline solution and ointment containing sulphanilamide, zinc oxide, cod liver oil, and camphor (Pomadol®), cold compresses and massage with a gel containing escin and diethylammonium salicylate (Reparil®) three times per day, for 7 days.

Material obtained via excisional biopsy was forwarded to the institution's Animal Pathology Service. Histopathology revealed micropapillary carcinoma with clear surgical margins and

presence of metastasis in axillary and inguinal lymph nodes.

Adjuvant therapy with antineoplastic chemotherapy was indicated, however, the owners declined for financial reasons, and agreed only to perform monthly follow-ups for systemic changes and distant metastasis investigation. During the first week after surgery, the patient did not experience complications. On the 30th day, all complementary exams were repeated. Results from blood tests, urinalysis, UP:UC and thoracic radiographs showed no changes. Ultrasonographic examination showed the same structure in the medial right hepatic lobe.

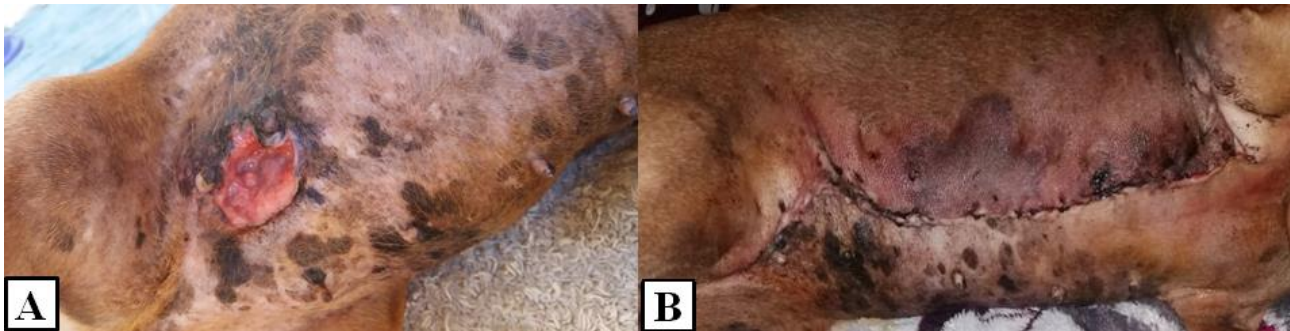
On the 60<sup>th</sup> day after surgery (Figure 3), the patient had an inflammatory reaction in the surgical site (axillary, thoracic, inguinal). Rigid, ulcerated nodulations were present on the medial surface of the right pelvic limb and in the perivulvar region. The patient had erythema and pain on palpation over the axillary, thoracic and inguinal regions. Blood tests, urinalysis, UP:UC and radiographs were repeated and showed no changes. Abdominal ultrasound revealed an increased hepatic nodule (3.57 cm x 2.0 cm) and on the site of recurrence (where the mammary gland used to be), there was a diffuse heterogenic lesion with areas of cavitation with anechoic content. Qualitative and quantitative ARFI elastography of the recurrent lesion was performed using the virtual touch tissue imaging quantification (2D-SWE technique) ARTI method VTIQ. The qualitative analysis generated color-scale images (elastogram) with darker tones (rigid and non-deformable) and the quantitative evaluation was performed to obtain shear velocity (m/s), showing an average velocity of 7.84 m/s (Figure 4).

Ultrasound-guided liver biopsies were performed with trucut needles, and two other incisional biopsies (one on the surgical scar from the mastectomy and the other on the ulcerated nodule on the medial surface of the pelvic limb) were also performed. Samples were sent to the institution's Animal Pathology Service. Biopsy samples for histopathological analysis were collected after plaque-shaped skin lesions were observed. Results showed metastasis of the micropapillary carcinoma, and liver biopsy results were consistent with glycogen degeneration associated with moderate fibrosis. The prescribed treatment was cephalexin at a dosage of 30 mg/kg B.I.D., ranitidine at 2 mg/kg B.I.D., tramadol

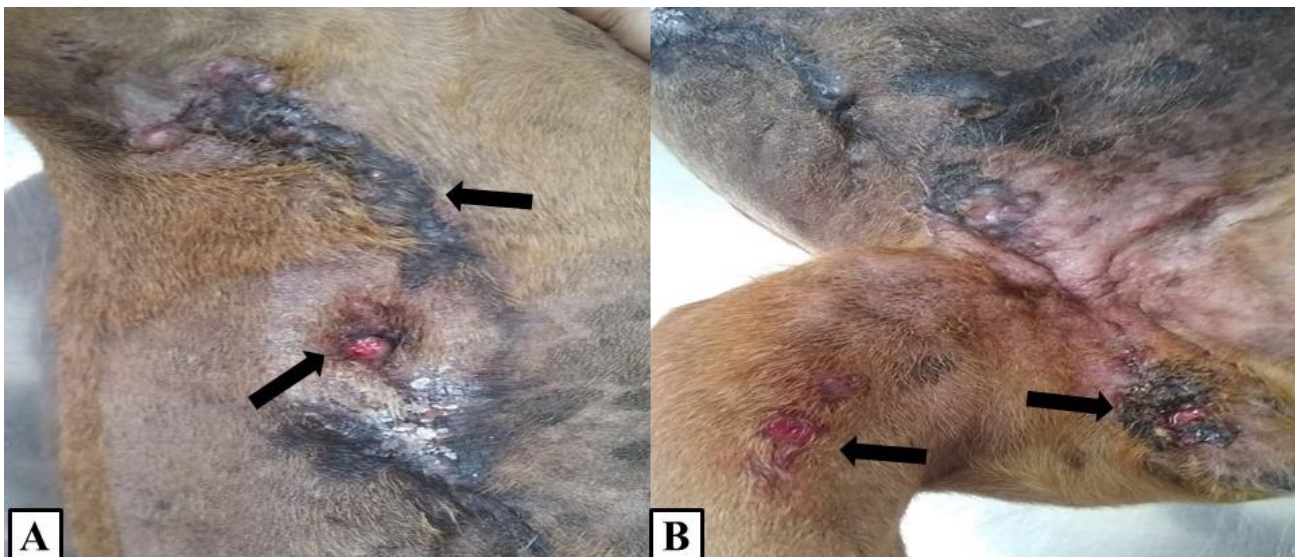

hydrochloride at 3 mg/kg/ T.I.D., gabapentin at 10 mg/kg B.I.D., and carprofen at 2.2 mg/kg/ B.I.D., all orally, for 7 days. The patient showed improvement for a period of 20 days. Afterwards, nodules increased in size and number in the

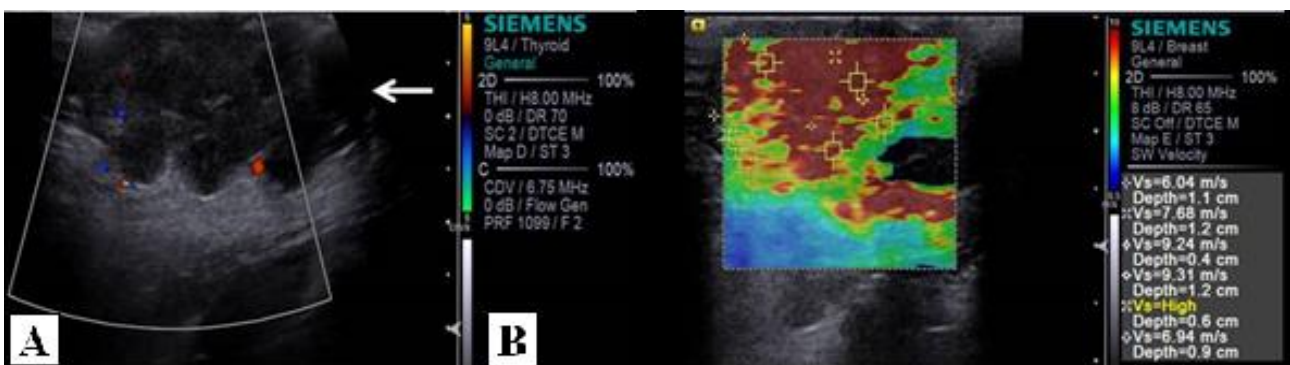
perivulvar, inguinal, abdominal, and right axillary regions, progressively ulcerating. There was edema on the medial surface of the pelvic limb, with moderate pain.



**Figure 2:** A) Photograph of patient with a mammary nodule. B) Postoperative, unilateral mastectomy with axillary and inguinal lymphadenectomy.



**Figure 3.** 60 days post-surgery. A) Ulcerated nodule (arrows). Inflammatory reaction (long arrow). B) Ulcerated nodule in the right pelvic limb (arrows). Perivulvar ulceration (long arrow).



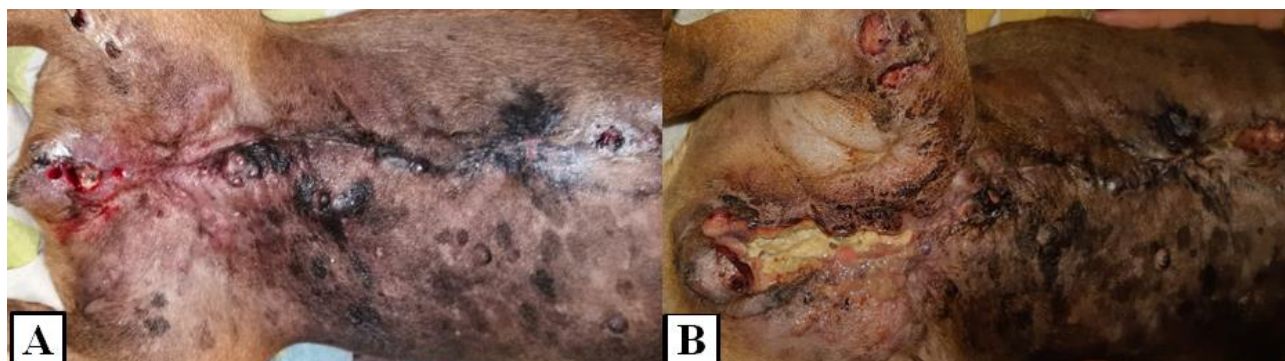**Figure 4.** Ultrasonographic images of the recurrent micropapillary carcinoma. A) Mammary gland with diffuse heterogeneity (arrow). B) ARFI qualitative and quantitative elastography of the recurrent micropapillary carcinoma. The elastogram shows darker tones (reddish) and the quantitative technique demonstrates increased shear velocity.

The patient returned on day 90 of the postoperative period (Figure 5) and all complementary exams were repeated. There was only leukocytosis on CBC, and there were no changes on other exams. The patient had

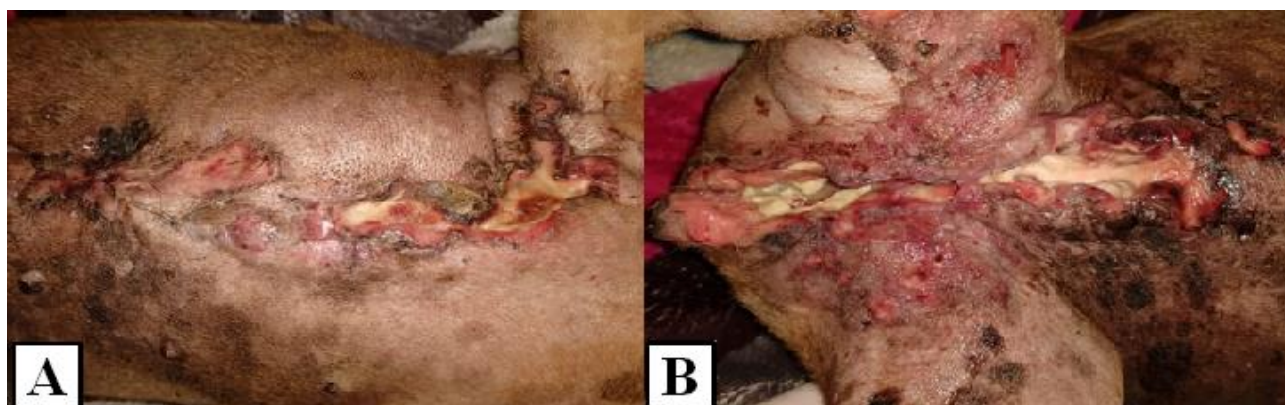oligodipsia and hyporexia. On physical examination, there was moderate pain, dysuria, and dyskinesia, apparently due to limited movement imposed by the referred hyperalgesia, in addition to the progression of the ulcerations,

with serous and hemorrhagic discharge. Supportive treatment was instituted. By the 100th day of treatment, the patient's condition evolved to severe pain and, consequently, restricted ambulation, urination, defecation, with food and

water consumption reduced by 70%, episodes of emesis and progression of ulcerative lesions. In order to avoid the installation of a dysthanasia process, on the 110th day after surgery (Figure 6), the patient was euthanized.



**Figure 5.** Photographic image of cutaneous metastasis of micropapillary carcinoma in a dog. A) Recurrent micropapillary carcinoma 70 days after surgery. B) Recurrent micropapillary carcinoma 90 days after surgery.



**Figure 6.** Photographic images of cutaneous metastasis of micropapillary carcinoma 110 days after surgery. A) Axillary and sternal region. B) Inguinal region, medial surface of the pelvic limbs and perivulvar region.

## Discussion

Gamba et al. (2013) reported that micropapillary carcinoma is a highly aggressive and invasive neoplasm, with high indices of regional lymph node metastasis. As described in this report, histopathological evaluation revealed the presence of inguinal and axillary lymph node metastasis at the time of the surgical procedure. However, even with unilateral mastectomy performed with clear surgical margins, the patient presented with recurrence and cutaneous metastasis over the scar line approximately 56 days after surgery.

In a retrospective study by Gamba et al. (2013), the average survival time of patients with micropapillary carcinoma was 120 days. Similar data were observed in the present case study, where survival time was 110 days. Nevertheless, a study by Franzoni et al. (2017) reported a 306-day survival with chemotherapeutic treatment (gemcitabine and carboplatin protocol) and the

use of a selective COX2 inhibitor (firocoxib). Adjuvant treatment was refused for financial reasons, but this supports the hypothesis that the addition of clinical cancer treatment is responsible for increasing the survival and improving quality of life of the patient, ensuring a greater control over the evolution of the neoplasm.

Salgado et al. (2013) described an inflammatory reaction two weeks after unilateral mastectomy, which occurred over the scar line. In a report of micropapillary carcinoma, Gamba et al. (2013) described an ulcerated skin lesion 21 days after surgery, which was diagnosed as micropapillary carcinoma with cutaneous metastasis. However, in the present report, an inflammatory reaction was observed at 56 days after mastectomy on the scar line and the medial surface of the pelvic limb. In these three reports, the patients were over 10 years of age, which may influence the prevalence of the disease. The right inguinal mammary gland was the most affected in



the reports, which may indicate an anatomical or physiological predisposition, however, as the volume of cases evaluated is small, given the rarity of occurrences with complete reports, further studies, also describing the location of the neoplasm, are indispensable.

As described by Feliciano et al. (2017), malignant mammary neoplasms have elastograms with dark colors and shear velocity above 2.57m/s in female dogs, supporting the findings in the present report, which demonstrated an average velocity of 7.84m/s. In addition, Feliciano et al. (2017) and Feliciano et al. (2018) suggest that elastography is recommended as a predictive technique for malignancy and/or prognosis, with a sensitivity of 94.7% and specificity of 97.2% in bitches with mammary neoplasms.

### Conclusion

It can be concluded that diagnosis is indispensable for management of an oncologic patient, since it allows implementation of the best treatment option for the cancer, aiming for a longer survival time with better quality of life.

### Conflict of Interest

The authors declare no conflict of interest.

### References

- Cassali, G.D.; Lavallo, G.E.; De Nardi, A.B.; Ferreira, E.; Bertagnolli, A.C.; Lima, A.E.; Alessi, A.C.; Daleki, C.R.; Salgado, B.S.; Fernandes, C.G.; Sobral, R.A.; Amorim, R.L.; Gamba, C.O.; Damasceno, K.A.; Auler, P.A.; Magalhães, G.M.; Silva, J.O.; Raposo, J.B.; Ferreira, A.M.R.; Oliveira, L.O.; Malm, C.; Zuccari, D.A.P.C.; Tanaka, N.M.; Ribeiro, L.R.; Campos, L.C.; Souza, C.M.; Leite, J.S.; Soares, L.M.C.; Cavalcanti, M.F.; Fonteles, Z.G.C.; Schuch, I.D.; Paniago, J.; Oliveira, T.S.; Terra, E.M.; Castanheira, T.L.L.; Felix, A.O.C.; Carvalho, G.D.; Guim, T.N.; Garrido, E.; Fernandes, S.C.; Maia, F.C.L.; Dagi, M.L.Z.; Rocha, N.S.; Fukumasu, F.G.; Machado, J.P.; Silva, S.M.M.S.; Bezerril, J.E.; Frehse, M.S.; Almeida, E.C.P.; Campos, C.B.. Consensus of the diagnosis, prognosis and treatment of canine mammary tumors. **Brazilian Journal of Veterinary Pathology**, 4(2): p. 153-180, 2011.
- Feliciano, M.A.R.; Silva, A.S.; Peixoto, R.V.R., Galera, P.D., Vicente, W.R.R. Estudo clínico, histopatológico e imunoistoquímico de neoplasias mamárias em cadelas. **Arquivo Brasileiro de Medicina Veterinária e Zootecnia**, 64(5): 1094-1100, 2012.
- Feliciano, M.A.R.; Uscategui, R.A.R.; Maronezi, M.C.; Maciel, G.S.; Avante, M.L.; Senhorello, I.L.S.; Mucédola, T.; Gasser, B.; Carvalho, C.F.; Vicente, W.R.R. Accuracy of four ultrasonography techniques in predicting histopathological classification of canine mammary carcinomas. **Veterinary Radiology & Ultrasound**, 59 (4): p. 444-452, 2018.
- Feliciano, M.A.R.; Uscategui, R.A.R.; Maronezi, M.C.; Simões, A.P.R.; Silva, P.; Gasser, B.; Pavan, L.; Carvalho, C.F.; Canola, J.C.; Vicente, W.R.R. Ultrasonography methods for predicting malignancy in canine mammary tumors. **PLoS ONE** 12(5): e0178143, 2017.
- Franzoni, M.S.; Rosa, V.A.; Silva, C.M.L.; Salvador, R.C.L; Amorim, R.L; Ferreira, T.M.M.R. Carcinoma mamário micropapilar metastático em cadela associado com sobrevida de 306 dias. **Investigação**, 16(1): 67-70, 2017.
- Gamba, C.O.; Dias, E.J.; Ribeiro, L.G.R.; Campos, L.C; Lima, A.E.; Ferreira, E.; Cassali, G.D. Histopathological and immunohistochemical assessment of invasive micropapillary mammary carcinoma in dogs: A retrospective study. **The Veterinary Journal**, 196: 241-246, 2013.
- Marchió, C.; Iravani, M.; Natrajan, R.; Lambros, M.B; Savage, K.; Tamber, N.; Fenick, K.; Mackay, A.; Senetta, R.; Di Palma, S.; Schmitt, F.C.; Bussolati, G; Ellis, I.O.; Ashworth, A.; Sapino, A.; Reis-Filho, J.S. Genomic and immunophenotypical characterization of pure micropapillary carcinomas of the mammary gland. **Journal of Pathology**, 215: 398-410, 2018.
- Ricci P.; Maggini, E.; Mancuso, E.; Lodise, P.; Cantisani, V.; Catalano, C. Clinical application of mammary gland elastography: State of the art. **European Journal of Radiology**, 83(3): 429-437, 2014.
- Salgado B. S.; Monteiro L. N.; Colodel M. M.; Figueiroa, F.C.; Soares, L.M.; Nonogaki, S.; Rocha, R.M.; Rocha, N.S. Clinical, cytologic, and histologic features of a mammary micropapillary carcinoma in a dog. **Veterinary Clinical Pathology**, 42(3): 382-385, 2013.
- Tang, S.; Yang, J.; Du, Z.; Tan, Q.; Zhou, Y.; Zhang, D.; Lv, Q. Clinicopathologic study of invasive micropapillary carcinoma of the mammary gland. **Oncotarget**, 8(26): 42455-42465, 2017.