



Ultrasonographic scan planes for sexing ovine and caprine fetuses¹

(Planos ultrassonográficos para sexar fetos ovinos e caprinos)

"Artigo Científico/Scientific Article"

EMP Azevedo, CR Aguiar Filho, LM Freitas Neto, RTD Moura, ER Santos Junior, MHB Santos, PF Lima, MAL Oliveira^(*)

Laboratório de Biotecnologia do Departamento de Medicina Veterinária - UFRPE, Av. Dom Manoel de Medeiros, s/n, Dois Irmãos, 52171 900 Recife-PE, Brasil.

Abstract

The present study emerged from the diagnostic difficulties found during the ultrasonographic examinations for fetal sexing, concerning to the different images obtained in the visualization of fetal structures. This work aimed to describe anatomic planes gotten in ultrasonographic images for localization and identification of the genital tubercle, umbilical cord, prepuce, scrotal bag, nipples and vulva in the sexing of embryos in goats and sheeps. The 280 embryos from 219 females were monitored at 24-hours interval, being examined goats between Days 40 and 60 and sheeps on Days 30 to 60 of pregnancy, with an ultrasound equipped with linear transducer (6.0-8.0 MHz), by transrectal via. The same technician executed all the examinations with the animal in station position. In this work, the fetal sex identification occurred in 207 (73.93%) cases through longitudinal plan. In the transverse plane was observed in 62 fetuses (22.14%) and the sagittal plane was obtained with only eleven (3.93%) sexed fetus. Among the reached planes, the ventral longitudinal plane was considered the most suitable for sexing goat and ovine fetuses, once it enables getting images of the initial period of genital tubercle migration, besides the visualization of other structures as umbilical cord, nipples and scrotal bag.

Keys-words: genital tubercle, scrotal bag, prepuce, nipples, vulva.

Resumo

O presente estudo surgiu das dificuldades diagnósticas encontradas durante os exames ultra-sonográficos para a sexagem fetal, sobre as imagens obtidas em diferentes visualizações das estruturas fetais. Este trabalho teve como objetivo descrever os planos anatômicos obtidos em imagens de ultrassonografia para a localização e identificação do tubérculo genital, cordão umbilical, prepúcio, bolsa escrotal, mamilos e vulva na sexagem em embriões de caprinos e ovinos. Os 280 embriões provenientes de 219 fêmeas foram monitorados em intervalos de 24 horas, sendo os caprinos examinados entre os dias 40 e 60 e os ovinos nos dias 30 a 60 de gestação, com um ultrassom equipado com transdutor linear (6.0-8.0 MHz), por via transretal. O mesmo técnico executou todos os exames com o animal em posição de estação. Neste trabalho, a identificação do sexo fetal ocorreu em 207 (73,93%) casos, através do plano longitudinal. No plano transversal foi observado em 62 fetos (22,14%) e no plano sagital foi obtida em apenas onze (3,93%) fetos sexados. O plano ventral longitudinal foi considerado o mais adequado para a sexagem de fetos caprinos e ovinos, uma vez que permite obter imagens do período inicial da migração do tubérculo genital, além da visualização de outras estruturas como o cordão umbilical, tetas e bolsa escrotal.

Palavras-chave: tubérculo genital, bolsa escrotal, prepúcio, tetas, vulva.

⁽¹⁾Trabalho extraído da Tese de Doutorado da primeira autora apresentado ao Programa de Pós-Graduação em Ciência Veterinária da Universidade Federal Rural de Pernambuco.

^(*)Autor para correspondência/Corresponding author (maloufrpe@uol.com.br).

^(§)Recebido 24/09/2008 e aceito em 26/03/2009.

Introduction

The raising of small ruminants in Brazil has increased in recent years due to the introduction of exotic species by importation of animals, semen and embryo with high genetic value, especially in the Northeastern region where the concentration of these animals are the highest in Brazil (IBGE, 2002).

Early fetal sex identification is of important value in the animal breeding industry. There are several methods for sexing embryos and fetuses and the methods give high accurate results at a very early stage of development of the embryo (Moura, 1993). Thus, the determination of the exact day of genital tubercle migration is still one of the main challenges of fetal sexing in small ruminants (Santos et al., 2006a). The first study on fetal sex identification in sheep was performed by Coughbrough and Castell (1998) and later by Bürstel et al. (2001/2002), Nan et al. (2001) and Andrade et al. (2004). However, only after Santos et al. (2006b) reports was possible to sex sheep and goat fetuses taking into consideration the final position of the genital tubercle.

Considering the inexistence of studies in this subject in small ruminants, the present study was undertaken to describe the ultrasonographic planes used to sex fetuses in goats and ewes, as well as to point out the ideal plane to locate and identify the genital tubercle, prepuce, scrotal bag, nipples and vulva.

Material and Methods

The 280 fetuses of the 219 pregnant females monitored at intervals of 24 hours were examined between Days 40 to 60 of pregnancy in goats and Days 30 to 60 in ewes.

Transrectal ultrasound was carried out with a 240 Parus (Pie Medical) apparatus equipped with a linear transducer (6.0 and 8.0 MHz), that was adapted to a PVC support to facilitate manipulation into the animal's rectum, as suggested by Oliveira et al. (2004). Pictures obtained by ultrasonography were

printed using a Sony printer (Seikosha VP/1200). The same technician performed all examinations with the animal in a standing position.

At the end of each scanning section, all printed images were assessed for a detailed analysis and confirmation of the obtained planes of view. In this experiment many different scanning planes were achieved and than described.

The longitudinal or dorsal plane view could be obtained by holding the transducer lateral, cranial or caudal to the fetal body; allowing the sound beam to pass through the fetus in a dorsal plane. This plane was achieved in three sections at different regions of the fetus body: close to the dorsum, at the midway level of the trunk and at the ventral portion of the abdomen.

The sagittal plane was achieved by holding the transducer dorsal, ventral, cranial or caudal to the fetal body, allowing the sound beam to pass through the fetus in sagittal plane. The sections of this plane were achieved leaving the sound beam pass exactly in the middle of the fetus body or moving the transducer slightly to the right or to the left side.

The transverse plane was achieved by holding the transducer dorsal, lateral or ventral to the fetal body, permitting the sound beam to pass through the fetus in transverse plane. This plane could be visualized in three sections achieved between the umbilicus and tail: caudal, inguinal and umbilical sections. Locating the umbilicus was helpful for the use of this technique. After finding the umbilical cord, which was usually imaged in longitudinal plane, on reaching the level of the attachment of the umbilical cord to the abdomen (umbilicus), the transducer was slowly moved to obtain a cross section of the umbilicus.

Oblique plane was obtained by holding the transducer angled toward the sides of the fetus. Sections in this plane could be obtained at the extreme caudal region, ventral abdominal wall, perineal region, inguinal

region and others. This plane was frequently seen as a deviation of one of the planes previously explained.

Results

Some of the smaller goats and ewes presented great problems with scanning, due to the narrowness of the rectum; and some were of poor temperament, leading to prolonged scanning.

There were many structures which could be ultrasonographically confused with the genital tubercle, due to a similar bilobar hyperechoic appearance. Locating fetal landmarks such as umbilical cord, heart beating and head was essential for orientation purposes.

With positive male diagnosis, a bilobar hyperechoic structure appeared near or in close proximity to the umbilicus, depending on the gestational age (Figure 1). Whereas for a positive female diagnosis, this structure was absent on scanning this region (Figure 2).

During the scannings it could be observed that in the same period of pregnancy some diagnoses were easier to achieve than others, even with fetus of the same sex. The images framed were also similar in some scannings and different in others. Evaluating these obtained images, at the moment of the scanning and later looking at the frames, could be observed that the anatomical planes of viewing of the fetuses varied according to the position of it to the sound beam that passed through its body. In fact, the way the fetus faced the transducer could give similar structure images for sexing both female and male fetuses, what was determined by the scanning plane obtained at the moment of the exam.

To image the relevant structures identifiable with the different genders within the fetal body, the longitudinal plane section should be situated more ventral than dorsal to the fetus body (Figure 3); otherwise, the hyperechoic structures used for deciding genders of the fetus could be confused with ribs, pelvic bones and even the umbilical region could probably not be imaged,

preventing early sex identification of the fetus. For both sexes, the genital tubercle and external genitalia were easily imaged in longitudinal view. This was a very reliable plane and also commonly achieved during the examinations. In this work, the fetal sex identification occurred in 207 (73.93%) cases through this plan.

Scanning in longitudinal plane at the level of the dorsum, did not enable visualization of the gender in early stage of differentiation of the gonad, once the genital tubercle is situated ventrally, between the hind limbs. In older females, the external genitalia could be visualized. The section of this plane at the level of the proximal region of the limbs (medial region of the abdomen), allowed the identification and location of the external genitalia in female, as well as the migrating genital tubercle. Rarely, this view provided visualization of the ventral portion of the rib cage, making difficult the identification of the genital tubercle at the abdomen, in the male fetus. This section usually exhibited the tail vertebrae in cross or longitudinal plane and the cross section of the limbs. A section at the extreme ventral region of the fetus showed the limbs, the tail and umbilicus in cross section; the latter could also be present in longitudinal view. Usually, the prepuce could be observed next to the umbilicus. Occasionally, the head could be visualized. In older female fetuses, the mammary gland could be observed (Figure 4).

In this study a section of the transverse plane at the extreme caudal region was observed in 62 fetuses (22.14%). This view could show the entire hind limbs or only parts of it. The scrotum, when present, was usually seen in longitudinal plane (Figure 5). In this view, a cross section of the vertebrae column could be visualized directly opposite to the scrotum. The mammary gland could be seen in older female fetuses also in cross section (Figure 6). In the ovine species, the tail could be seen in cross section at the level of its insertion with the fetal body, resembling the ultrasonographic appearance of the genital tubercle. Sometimes the tail could be seen in

longitudinal plane, running distal to the body preventing visualization of the fetal genitalia in this species. The umbilicus was usually not present in this image, but occasionally could be seen in both cross section and longitudinal plane.

This plane with a section between the umbilicus and the hind limbs (inguinal) provided visualization of the scrotum in longitudinal plane, when this was present. Occasionally, female fetuses that had the genitalia already resembling that of the adult could be framed (Figure 7) and the prepuce could be imaged close to the longitudinal view of the umbilical cord (Figure 8).

Part of the ventral region of the animal could also be seen, but the umbilicus was not visible. It was clearly noticed that the hind limbs were cranially imaged. In the male fetus, the genital tubercle could be seen as a hyperechoic structure at the ventral region of the abdomen. When the scrotum was present, it could be visualized in a longitudinal plane pendent from the abdomen, between the hind limbs, or in cross section at the same region (Figure 9).

The section of the transverse plane at the level of the umbilicus showed the genital tubercle, seen as a hyperechoic round structure at the ventral wall of the abdomen, near or in close proximity to the umbilicus. The umbilical cord could be imaged in longitudinal plane in this section when running perpendicular to the ventral abdominal wall of the fetus. A cross section of

the umbilical cord was the most reliable way to achieve a diagnosis. Both the prepuce and scrotum were usually present in the same image, however, the former was difficult to discern. To image the prepuce and scrotum, the section had to reach a larger portion of the ventral abdominal region and extend caudally.

The sagittal plane of the fetus was rarely obtained with only eleven (3.93%) sexed fetus. This plane was not consistent in early stages of differentiation of the gonad, since the migration of the genital tubercle could be at its initial stage and ultrasonographic visualization was difficult. The position of the hind limbs could occasionally prevent location of the genital tubercle in early stages of differentiation, and at times the hind limb bones could be confused as the tubercle in an after stage of migration of the organs differentiation of gender, the sex could be easily discerned by location of the external genitalia under the tail or close to the umbilicus, for female and male respectively. At stages in which the scrotum was already present, this could be missed when one of the hind legs was on the near plane of the image, leaving the scrotum in the background of the frame. When imaged in this plane, the umbilical cord was always seen in longitudinal view. At figure number 10 is observed a female in this plane identifying the vulva close to the tail, however the visualization of the nipples was difficult because the hind limbs position.

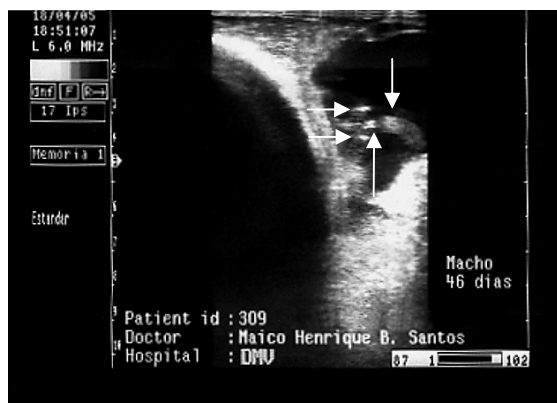


Figure 1 - Longitudinal plane at the extreme ventral region of the fetus. Ovine male fetus on Day 46, exhibiting a hyperechoic image of the genital tubercle (↑) located caudally to the umbilicus (↓), showing the hind limbs (→).

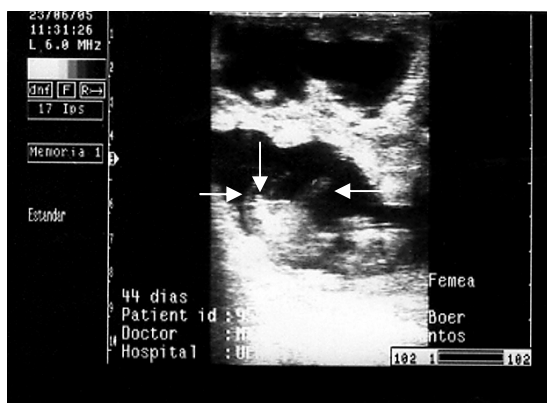

Figure 2 - Sagittal plane of a caprine female fetus on Day 44 of pregnancy, showing hyperechoic image of the genital tubercle (↓) located near the tail (→), visualize the umbilical cord (←) (SANTOS et al., 2006b).

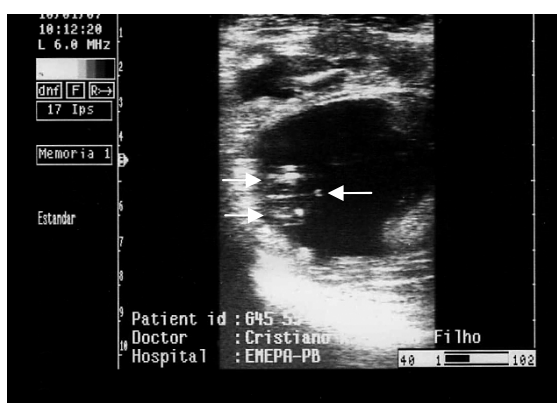


Figure 3: Longitudinal plane at the extreme ventral region of a caprine male fetus on Day 55, visualizing the prepuce (←) and the hind limbs (→).

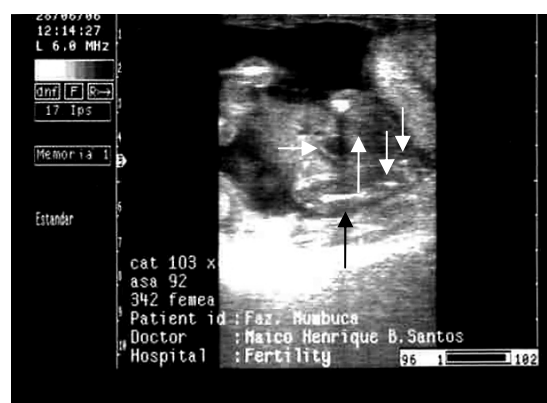

Figure 4: Longitudinal plane at the extreme ventral region of a caprine female fetus on Day 60 visualizing the nipples (↓) between the hind limbs (↑), with the umbilical cord (→) cranial.

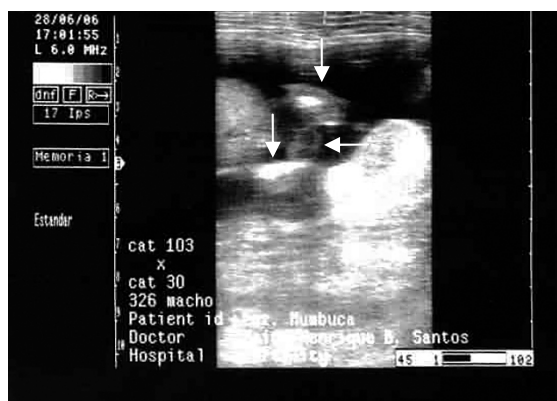

Figure 5: Longitudinal plane at the extreme ventral region of the caprine male fetus on Day 60; exhibits the scrotum (←) between the hind limbs (↓).

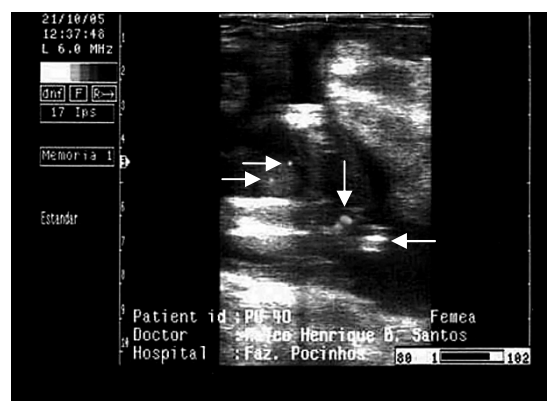


Figure 6: Transverse plane at the perineal region, observe the image hyperechoic of the nipples (→) between the hind limbs, showing the vulva (↓) and the tail (←) (SANTOS et al., 2007a).

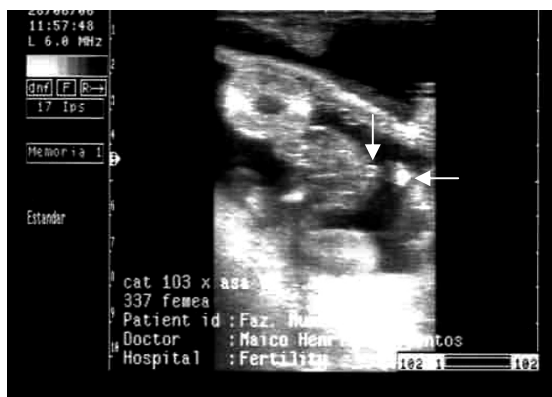

Figure 7: Transverse plane of a caprine female fetus on Day 60, visualize an image hyperechoic of the vulva (↓) near to tail (←).

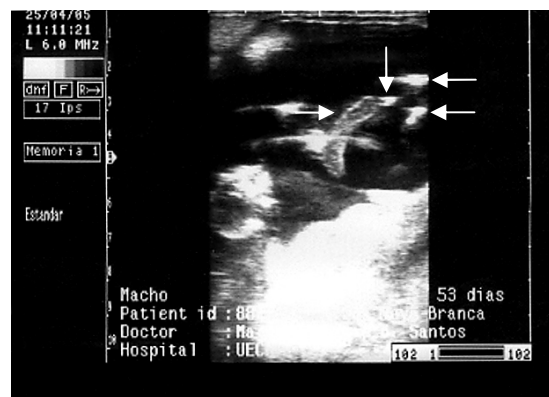


Figure 8: Longitudinal plane of caprine male fetus on Day 53, showing an image hyperechoic of the prepuce (↓) caudally to the umbilical cord (→), the hind limbs are visualized (←).

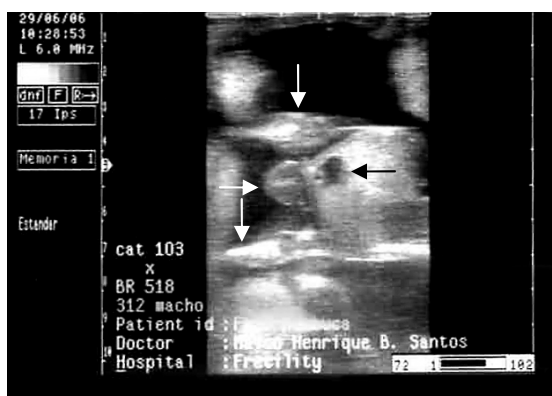


Figure 9: Transverse plane at the level of umbilical cord of a caprine male fetus on Day 60, with the scrotum (→) between the hind limbs (↓); visualize the insert of the umbilical cord (←) on the abdomen.

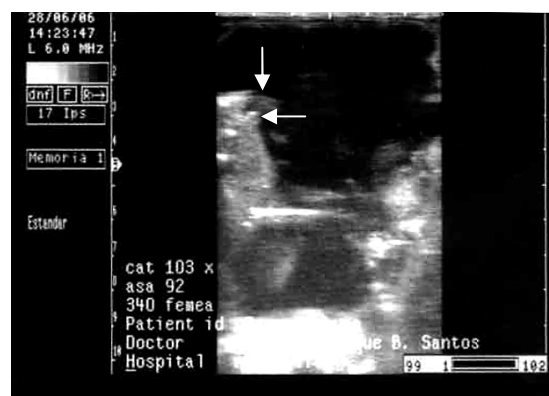


Figure 10: Sagittal plane of an ovine female fetus on Day 60, observed an image hyperechoic of the vulva (←) near to the tail (↓).

Discussion

In this work the ultrasonographic identification and location of the genital tubercle and fetal external genitalia in early gestational stage allowed identification of the sex. Same results were previously obtained by Coubrough and Castell (1998), Bürstel et al. (2001/2002), Nan et al. (2001), Andrade et al. (2004), Santos et al. (2006ab/2007), Azevedo et al. (2009).

The genital tubercle is the embryonic structure present in both male and female that differentiates into the penis and clitoris in male and female fetuses respectively (Noden and De La Hunta, 1985). During the process

of differentiation, the genital tubercle migrates from its initial position, between the hind limbs, towards the umbilicus in males and towards the tail in females. The genital tubercle was ultrasonographically seen as a hyperechoic structure usually presenting a bilobar appearance, corroborating with Inomata et al. (1982).

Determination of the relative location of the genital tubercle was dependent upon the plane of scanning. Visualization and location of the gender of the fetus was possible through sagittal, longitudinal and transversal (cross section) planes in goats and ewes fetuses, according to Bürstel (2002), and in

bovine, also adding the oblique plane, according to Moura (1993). Corroborating with this authors, the number of samples obtained in this work suggested a wide variety of planes of view of the fetus, which was helpful in locating and identifying the fetus sex.

In this work it was observed difference in the ultrasonographic appearance of the genital tubercle on different days of early stages of its differentiation and also in the plane that it was imaged, what is in agreement with Moura (1993).

The visualization of fetal structures, in both genders, was observed in all the described planes and their sections. However, some planes difficulty the visualization of those structures because the position of the body, hind limbs and umbilical cord of the fetus, as mentioned by Moura (1993).

The sagittal plane permitted an easy identification of the prepuce and vulva in older fetuses, corroborating with Moura (1993) results. This plane, however, was rarely achieved and seemed to produce inconstant results in the early stages of migration of the gender. Owing to the small size of the external genitalia at early stages of development, it could be easily missed by the presence and movement of the hind limbs seen in this view, as previously reported by Curran et al. (1989) and Moura (1993).

In this work, the transverse plane of the fetus at the level of the umbilical region (umbilical section) or caudal to it (inguinal section) proved to be a consistent useful plane of view for sexing. In the male, the genital tubercle could be seen close to the umbilicus and also the longitudinal presentation of the scrotum, when this was already formed. A section at the extreme caudal region (extreme caudal section) gave a good view for identification of the genital tubercle or external genitalia in females, and also the scrotal bag when it was already developed, corroborating with Curran et al. (1989) and Moura (1993).

Transverse plane appeared to be most useful for routine use, because the bilobed

morphology is distinct, and it was convenient, for orientation purposes, to first locate the head and beating heart in cross section and then to move the transducer caudally across the fetus, to obtain sequential transverse plane sections, according to Moura (1993); however, Barros and Visintin (2001) relate that the transverse plane makes thorny diagnosis in males and females, because fetus landmarks need to be visualized in several planes to determine the positioning of the tubercle, being more difficult in females, due to the presence, at the same plane, of the sacred, ischium and coccyges vertebrae. In this research work, the transverse plane showed to be one of the most reliable planes of view, depending on the period of gender differentiation and the section scanned.

According to Moura (1993) and Barros and Visintin (2001), the longitudinal plane provided the best images and gave an easy location of the gender. In this work the fetus could be imaged in its entire length in this plane, showing the umbilical and perineal regions, enabling identification and location of the genital tubercle and other structures of the external genitalia, besides important landmarks as umbilical cord, tail and hind limbs.

According to Barros and Visintin (2001), in cows the appearance of the fetus in longitudinal plane at the section lateral make easy the diagnosis of the sex, because there were observed, in a single image, the previous members, thorax, umbilical cord, hind limbs, tail and genital tubercle, visualizing in many cases the anogenital raphe and the scrotal bag in males and the nipples in females, what was also observed in the species used in this work.

Still according to these authors, this image shows the exact view of the positioning of the genital tubercle in males, but in females the genital tubercle comes close to the sacred and coccyges vertebrae, hindering longitudinal plane diagnostic. In the longitudinal back-ventral plane it is possible a wide vision of the fetus, this simplifies the diagnosis in males and females, which show the genital tubercle right below the tail. In this

research work in small ruminants, it was observed some similarity in certain scanning planes mentioned by the above mentioned authors, but our work defined sections differently of those cited by them, what turn difficult to compare some planes of view.

The oblique plane was usually obtained as a deviation of the dorsal and transverse planes and presented difficulties to properly locating the genital tubercle and external genitalia in these specie. Always partially showing the fetus and also seemingly to show the fetus as if it was reduced, several oblique sections gave rise a doubt to correctly identify the sex of the fetus. Some images obtained showed the genital tubercle in close proximity to the umbilicus and the presumptive genital swellings between the hind limbs, distant of the genital tubercle. The distance between the structures would not match with the gross morphological findings of the external genitalia at this age, as reported in Moura (1993).

The cross section view of the umbilical cord appeared to be the most reliable way for diagnosis, as mentioned by Curran et al. (1989) and Moura (1993). However, in this work, a cross section of the umbilical cord, at the base of its attachment to the abdominal region, occasionally exhibited hyperechoic areas which could be mistaken with the genital tubercle. These areas of hyperechogenicity may be referred to the wall of the umbilical veins or also some internal structure of the fetal body close to the region of the umbilical attachment, corroborating with Moura (1993).

Conclusion

The determination of the plane of view had to be carefully carried out before the location of the fetus gender be evaluated. It was convenient to first look for fetal landmarks for orientation purposes and also detailed observation of other embryonic structures with ultrasonographic appearance similar to that of the genital tubercle. Therefore, if the ultrasonographer attempted

to hurry the examination, misinterpretations could be made.

The longitudinal plane represents the most suitable plane to sex male and female caprine and ovine fetuses at any stage of development of the gender, once the moving of the transducer to get the different sections in this plane was easily achieved and the visualization of the entire fetus abdomen and caudal region was possible, enabling identification of the fetus sex structures and landmarks and also the measurement of distance among them.

References

- ANDRADE, J.C.O. et al. Fetal sexing in ewes. *Acta Scientiae Veterinariae*, n.32, p.185, 2004.
- AZEVEDO, E.M.P. et al. Migration time of the genital tubercle caprine and ovine fetuses: comparison between breeds, sexes and species. *Acta Veterinaria Hungarica*, v.57, n.1, p.147-154, 2009.
- BARROS, B.J.P.; VISINTIN, J.A. Ultrasonic control of early pregnancies, embryonic and fetal mortalities and fetal sex in zebu cattle. *Brazilian Journal of Veterinary Research and Animal Science*, v.38, n.2, p.74-79, 2001.
- BÜRSTEL, D. **Untersuchungen zur intrauterinen Geschlechtsfeststellung bei Feten kleiner Wiederkäuer mittels Ultrasonographie**. 2002. Ph Dissertation (Institut für Reproduktionsmedizin) - Tierärztliche Hochschule, Hannover.
- BÜRSTEL, D. et al. Ultrasonographic determination of fetal sex in small ruminants. In: ANNUAL CONFERENCE OF THE EUROPEAN SOCIETY FOR DOMESTIC ANIMAL REPRODUCTION, 5th. 2001. Vienna. **Proceeding...** Vienna: **ESDAR Newsletter**, 2001. v.6, p. 53-54.
- BÜRSTEL, D. et al. Ultrasonographic diagnosis of fetal sex in small ruminants bearing multiple fetuses. *Veterinary Record*, v.151, n.21, p.635-636, 2002.
- COUGHBROUGH, C.A.; CASTELL, M.C. Fetal sex determination by ultrasonically locating the genital tubercle in ewes. *Theriogenology*, v.50, n.4, p.263-267, 1998.

- CURRAN, S. et al. Determining sex of the bovine fetus by ultrasonic assessment of the relative location of the genital tubercle. **Animal Reproduction Science**, v.19, p.217-227, 1989.
- IBGE. Anuário Estatístico do Brasil, Rio de Janeiro, 58, pp.3-54, 2002.
- INOMATA, T. et al. Development of the external genitalia in bovine fetuses. **Japanese Journal of Veterinary Science**, v.44, p.489-496, 1982.
- MOURA, R.T.D. **Ultrasonographic Studies on Early Bovine Pregnancy Diagnosis and Foetal Sexing**. 1993. Master thesis (Department of Veterinary Anatomy) - University of Glasgow.
- NAN, D. et al. Determination of foetal gender in sheep by transabdominal ultrasonographic scanning. In: ANNUAL CONFERENCE OF THE EUROPEAN SOCIETY FOR DOMESTIC ANIMALS REPRODUCTION, 5th. 2001. Vienna. **Proceedings...** Vienna: **ESDAR Newsletter**, 2001. v.6, p.70.
- NODEN, D.M.; De LAHUNTA, A. The embryology of domestic animals: Developmental mechanisms and malformations. Williams and Wilkins, Baltimore, MD, USA. 1985. 367p.
- OLIVEIRA, M.A.L. et al. Aplicabilidade do Scan B na reprodução de pequenos ruminantes. In: SANTOS, M.H.B. et al. **Diagnóstico de gestação na cabra e na ovelha**. São Paulo: Varela, 2004. Cap.13, p.85-96.
- SANTOS, M.H.B. et al. Fetal sexing in Santa Inês ewes by ultrasonography. **Ciência Rural**, v.36, p.573-578, 2006a.
- SANTOS, M.H.B. et al. Sexing of Boer goat fetuses using transrectal ultrasonography. **Animal Reproduction**, v.3, n.3, p.359-363, 2006b.
- SANTOS, M.H.B. et al. Determination of the genital tubercle migration period in Morada Nova sheep fetuses by ultrasonography. **Reproduction in Domestic Animals**, v.42, p.214-217, 2007.