



Sexing of Savana goat fetuses using transrectal ultrasonography

(Sexagem de fetos caprinos da raça Savana utilizando ultra-sonografia transretal)

"Artigo Científico/Scientific Article"

MHB Santos^A, CR Aguiar Filho^B, LM Freitas Neto^B, ER Santos Júnior^B,
VJF Freitas^C, JP Neves^D, PF Lima^B, MAL Oliveira^{B(*)}

^ABolsita (BFP) da Fundação de Amparo à Ciência e Tecnologia do Estado de Pernambuco (FACEPE), Rua Benfica, 150, Madalena, 50720 001 Recife-PE/Brasil.

^BLaboratório de Biotécnicas Aplicadas à Reprodução do Departamento de Medicina Veterinária da Universidade Federal Rural de Pernambuco. Av. Dom Manoel de Medeiros s/n, Dois Irmãos, 52171-900 Recife-PE/Brasil.

^CLaboratório de Fisiologia e Controle da Reprodução da Faculdade de Veterinária da Universidade Estadual do Ceará. Av. Paranjana, 1700, Campus do Itapery, 60740 000 Fortaleza-CE/Brasil.

^DFaculdade de Agronomia e Medicina Veterinária, UNB, Campus Universitário Darcy Ribeiro, 70910-900 Brasília-DF/Brasil.

Abstract

In this study the goal was to establish the ideal period for sexing of Savana breed fetuses using transrectal ultrasonography. The daily exams were performed between Days 40 and 60 of pregnancy, to diagnostic the sex of fetuses based on the final position of the genital tubercle (GT). The transrectal exams were conducted using a dual-frequency, linear-array transducer (6.0 and 8.0 MHz) and the fetuses were monitored at 24-hour intervals. The accuracy of fetal sexing was 100% (20/20) for single pregnancies, 100% (29/29) for twin pregnancies, and 100% (29/29) for triplet pregnancies. The GT migration occurred between 45 and 55 days of pregnancy (mean = 48.7 ± 1.7 days). In conclusion, the use of ultrasound for sexing goat fetuses is a suitable and accurate method based on the final location of the GT from Day 55 of pregnancy onwards. Daily exams do not increase the accuracy of fetal sex diagnosis in Savana goats.

Key-words: sex, fetus, genital tubercle, vulva, scrotal bag, nipples.

Resumo

Nesse estudo teve-se o objetivo de estabelecer o período ideal para sexar fetos da raça Savana utilizando a ultrasonografia transretal. Os exames foram diariamente realizados entre o 40º e o 60º dia de prenhez para diagnosticar o sexo de fetos com base na posição final do tubérculo genital (TG). Os exames foram conduzidos com um transdutor linear de dupla frequência (6.0 e 8.0 MHz) com os fetos sendo monitorados a intervalos de 24 horas. A acurácia da sexagem fetal foi de 100% (20/20) na prenhez simples, 100% (29/29) na dupla e de 100% (29/29) na tríplice. A migração do TG ocorreu entre o 45º e o 55º dia da prenhez (média = 48,7 ± 1,7). Concluindo, pode-se afirmar que o ultra-som para sexar fetos caprinos com base na posição final do TG é um método apropriado e eficaz a partir do 55º dia de prenhez e que exames diários não aumentam a acurácia da sexagem de fetos caprinos da raça Savana.

Palavras-chave: sexo, fetos, tubérculo genital, vulva, bolsa escrotal, tetas.

(*) Autor para correspondência/Corresponding author (maloufrpe@uol.com.br; malo@dmv.ufrpe.br).

Introduction

The northeast region of Brazil, which is characterized by a semi-arid climate, has 93.7% of the country's goat population; however, the productivity of the local goats is low because most of these animals are derived from native and undefined breeds (BANDEIRA et al., 2004). One strategy often used in order to enhance productivity of the Brazilian local meat-type goat herds is to import animals, semen and embryos. Once imported, these animals are either maintained as a pure genetic material or crossbred with local goat breeds (RIBEIRO, 1997).

Savana breed, originated in South Africa in 1957, shows a high productive and reproductive performance, being specialized in meat production (VILELLA et al., 2005). The importing of animals, semen and embryos was intensified to enhance the existing native goat herds in Brazil.

Application of transrectal real-time ultrasonography as a research tool for the study of caprine reproduction represents a technological breakthrough that has revolutionized our understanding of goat reproductive biology (OLIVEIRA et al., 2004; MESSIAS et al., 2004; REICHENBACH et al., 2004; SANTOS et al., 2004ab).

Early diagnosis of pregnancy and fetal sexing using ultrasonography enhances reproductive management on farms and improves the commerce of pregnant animals (REICHENBACH et al., 2004; SANTOS et al., 2004b). Fetal gender identification, mainly in goats, is a technique hardly diffused throughout the world compared to cattle (MULLER and WITTKOWSKI, 1986; CURRAN, 1992; STROUD, 1996), horses (CURRAN and GINTHER, 1991; MERKT and MOURA, 2000), and sheep (COUGHBROUGH and CASTELL, 1998; BÜRSTEL et al. 2001/2002; BÜRSTEL, 2002, ANDRADE et al., 2004, SANTOS et al., 2005b/2006b/2007bcf). In Brazil, research has been stimulated regarding the sexing of fetuses in small ruminants, especially goats (SANTOS et al., 2005b/2006c).

A factor that has to be considered in order to increase the accuracy of sexing goat fetuses is the determination of a suitable period during gestation to perform the procedure taking into consideration time of completion of genital tubercle (GT) migration. Defining this period in these animals will improve the use of fetal sexing for either scientific or commercial goals (SANTOS et al., 2005a/2006a/2007ade).

The goal of this study was to establish the ideal period for sexing Savana fetuses using transrectal ultrasonography through a series of daily exams, between Days 40 and 60 of pregnancy, to diagnostic the sex of fetuses based on the final position of the GT.

Material and Methods

This study used 78 Savana fetuses derived from natural mating. All females were mated only once, and the day of mating was considered Day 0 of pregnancy.

Transrectal ultrasonography, performed by the same experienced technician, of animals in a standing position was carried out using a Aquila-Pro (*Pie Medical, Maastricht - Netherlands*) ultrasound scanner equipped with a dual-frequency, linear-array transducer (6.0 and 8.0 MHz) that was fixed to a PVC support to facilitate manipulation of the transducer inside the animal's rectum as suggested by Oliveira et al. (2004). Pictures obtained by ultrasonography were printed using a Seikosha VP/1200 printer (*Sony, Tokyo - Japan*). To perform the exam, females had their rectums manually evacuated and an ultrasonic coupling gel was applied to the transducer before its introduction into the rectum.

After insertion of the transducer into the rectum and having located the fetus, a scanning technique for fetal sexing was established. Determination of the sex was based on the identification and location of the GT relative to the location of umbilical cord attachment or tail from different scanning planes according to Azevedo (2007).

The fetuses were monitored daily between Days 40 and 60, and the sex was diagnosed as a male when the GT was located

immediately caudal to the umbilical cord or as female when the GT was positioned directly below the tail (Figura 1).

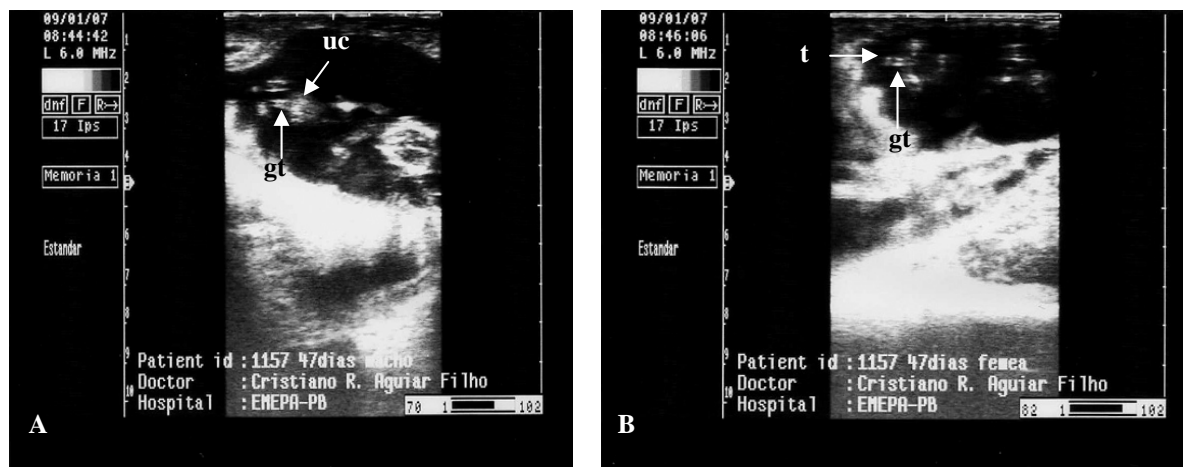


Figure 1- Ultrasound images of a male fetus (A) showing the genital tubercle (gt) located immediately caudal to the umbilical cord (uc) and of a female fetus (B) highlighting the genital tubercle (gt) in close proximity to the tail (t).

In the last week of pregnancy, the females were transferred to individual pens to confirm the sex of fetuses immediately after birth.

The results were analyzed by the chi square test using a significance level of $P < 0.05$.

Results

In this experiment, 20 females had a single fetus while 58 had multiple fetuses of which 29 had twin and 29 had triplet pregnancies. No differences were detected in the accuracy of fetal sexing among the different types of pregnancies (Table 1). The identification of fetal sex by location of the GT varied from Day 45 to 55 (Figure 2) with a mean of 48.7 ± 1.7 . For most of the fetuses

(66/78), the GT migration was completed between Days 47 and 50. For some fetuses (5/78), completion of GT migration occurred after Day 50 of pregnancy.

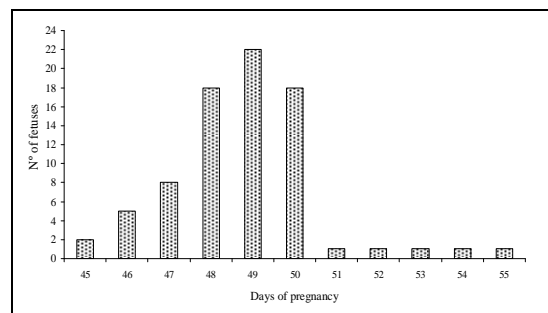


Figure 2 - Day of pregnancy when migration of genital tubercle was complete in Savana goat fetuses.

Table 1 - Fetal sexing of Savana goat fetuses by daily ultrasonographic monitoring between 40 and 60 days of pregnancy.

Kind of pregnancy	Correctly sexed fetuses		Unsexed fetuses (n)	Live kid (n)	Accuracy of diagnosis [n (%)]
	(n)	(n)			
Single	20	0	20	20/20 (100)	
Twin	29	0	29	29/29 (100)	
Tripled	29	0	29	29/29(100)	
Total	78	0	78	78/78 (100)	

Discussion

The GT was identified by Coubrough and Castell (1998) as single echogenic spot, it was not resolvable into two lobes, and the authors mentioned that this occurrence was presumably due because of the smaller size of ovine fetuses. On the other hand, in this work the GT was identified as into two lobes (Figure 1) as described for cattle (MULLER and WITTKOWSKI, 1986) and horses (CURRAN and GINTHER, 1991). The better results of this work, when compared to those obtained by Coughbrough and Castell (1998), should be attributed to the quality of the ultrasound apparatus. The dual frequency of the linear array transducer, the enlargement of images, the possibility of retrieving images produced in the last 30 seconds of the exam, and freezing images to get a better detail were important to the success of fetal sexing.

In this study, the period for fetal sexing based on the final position of GT did not differ from those found by Santos et al. (2005a/2006a/2007ade) for other goat breeds. Even though the GT migration was completed by Day 50 for most fetuses and this supports the recommendation of Santos et al. (2005a/2006a/2007ade) to begin sexing of goat fetuses only after Day 55 of pregnancy due to the wide range of time of completion of GT migration. It is important to emphasize that the migration occurred after this day in an insignificant number of fetuses and this data is shared with Santos et al. (2005/2007eg); however, does not in agreement with Santos et al. (2006a/2007ad), who related that the GT migration was completed after Day 50 in a considerable number of Boer fetuses.

It is also important to mention that the GT of some fetuses may complete migration after Day 55. A few studies, which determined the timing of GT migration in sheep (SANTOS et al., 2005b/2006b/2007bcf) and goats (SANTOS et al. 2005a/2007adeg; AZEVEDO, 2007), indicate that the timing of GT migration differs among species, animals of the same or different breeds, and fetuses of the same pregnancy.

Fetal sexing demands a skilled technician and use of adequate ultrasound equipment to allow a quick and accurate diagnosis. This recommendation is particularly important for female fetuses because the final location of the GT is relatively close to its initial position. For this reason, there are incorrect diagnoses; however, this can be reduced by a later exam that allows the visualization of the GT in its final position or identification of other structures of external genitalia.

The biggest challenge of fetal sexing using ultrasound in small ruminants compared to horses and cattle that affects accuracy of the diagnosis is the decreased ability to manipulate the uterus during the examination in small ruminants. Repeated ultrasound examinations of the same animal are required to accurately identify the fetal gender, as suggested by Bürstel (2002) and Reichenbach et al. (2004). However, exams done at short intervals are less feasible in the field because they can increase expenses. This could threaten the use of the technique that, if well managed, could maximize not only animal husbandry and commercial planning of the property as reported by Haibel (1990) and Reichenbach et al. (2004), but also animal productivity.

Dependent on the day of pregnancy and the number of fetuses, it is not always possible to quantify all fetuses in multiple pregnancies or even identify gender of all fetuses during a single exam. This observation agrees with Reichenbach et al. (2004) who, besides using more sophisticated equipment and skilled technicians, recommended serial exams for multiple pregnancies.

The initial expectation for differences in the accuracy of fetal sex determination between single and multiple pregnancies (especially in triplets) was not confirmed in this study. The most difficult pregnancy for fetal sexing is the multiple pregnancy, which is in agreement with White et al. (1984), Gearhart et al. (1988), and Haibel (1990) as well as with Bürstel et al. (2001) who

proposed exams be conducted during two consecutive periods, Days 50 and 56 and Days 66 and 70. The latter authors recommend multiple exams for fetal sexing restricted to triplet pregnancies because the presence of more fetuses increases the risk of failures in diagnoses. This opinion is shared by White et al. (1984), Gearhart et al. (1988), Haibel (1990), and Santos et al. (2005a/2006a/2007dg).

The results of this experiment show that real-time ultrasound scanning is an accurate method for sexing Savana fetuses from Day 55 of pregnancy onwards either by locating the GT or by identifying external genitalia. Repeated scanning at short intervals did not increase the accuracy of fetal sex diagnosis in this species.

Referências

ANDRADE, J.C.O. et al. Sexagem fetal em ovinos. *Acta Scientiae Veterinariae*, v.32, p.185, 2004.

AZEVEDO, E.M.P. **Utilização da ultrasonografia em ovinos e caprinos para sexar fetos e estimar a idade e o peso fetal ao nascimento.** 2007. 87f. Tese (Doutorado em Ciência Veterinária) – Universidade Federal Rural de Pernambuco.

BANDEIRA, D.A. et al. Aspectos da caprino-ovinocultura no Brasil e seus reflexos produtivo e reprodutivo. In: SANTOS, M.H.B. et al. **Diagnóstico de gestação na cabra e na ovelha.** São Paulo: Varela, 2004. Cap.1. p.1-9.

BÜRSTEL, D. **Untersuchungen zur intrauterinen Geschlechtsfeststellung bei Feten kleiner Wiederkäuer mittels Ultrasonographie.** 2002. 142f. Tese (Doutorado em Medicina Veterinária) - Institut für Reproduktionsmedizin, Tierärztliche Hochschule Hannover.

BÜRSTEL, D. et al. Ultrasonographic determination of fetal sex in small ruminants. ANNUAL CONFERENCE OF THE EUROPEAN SOCIETY FOR DOMESTIC ANIMAL REPRODUCTION. 5, 2001, Vienna. **Proceeding...** Vienna: ESDAR Newsletter, 2001. v.6, p.53-54.

BÜRSTEL, D. et al. Ultrasonographic diagnosis of fetal sex in small ruminants bearing multiple

fetuses. *Veterinary Record*, v.151, n.21, p.635-636, 2002.

COUBROUGH, C.A.; CASTELL, M.C. Fetal sex determination by ultrasonically locating the genital tubercle in ewes. *Theriogenology*, v.50, p.263-267, 1998.

CURRAN, S. Fetal sex determination in cattle and horses by ultrasonography. *Theriogenology*, v.37, p.17-21, 1992.

CURRAN, S.; GINTHER, O.J. Ultrasonic determination of fetal gender in horses and cattle under farm conditions. *Theriogenology*, v.36, p.809-814, 1991.

GEARHART, M.A. et al. Real-time ultrasonography for determining pregnancy status and viable fetal numbers in ewes. *Theriogenology*, v.30, p.323-337, 1988.

HAIBEL, G.K. Use of ultrasonography in reproductive management of sheep and goat herds. *Veterinary Clinics of North America: Food Animal Practice*, v.3, p.597-613, 1990.

MERKT, H.; MOURA, J.C.A. Geschlechtsbestimmung von Pferdefeten zwischen dem 50. und 93. Tag der Trächtigkeit mittels Sonographie. *Tierärztliche Praxis*, v.28, p.166-171, 2000.

MESSIAS, JB. et al. Estimativa da idade e do peso embrionário e fetal através da ultra-sonografia. In: SANTOS, MHB et al. (Eds.) **Diagnóstico de gestação na cabra e na ovelha.** São Paulo: Varela, 2004. p.149-157.

MÜLLER, E.; WITTKOWSKI, G. Visualization of male and female characteristics of bovine fetuses by real-time ultrasonics. *Theriogenology*, v.25, p.571-574, 1986.

OLIVEIRA, M.A.L. et al. Aplicabilidade do scan B na reprodução de pequenos ruminantes. In: SANTOS, M.H.B. et al. **Diagnóstico de gestação na cabra e na ovelha.** São Paulo: Varela, 2004. Cap.13. p.85-96.

REICHENBACH, H.D. et al. Sexagem fetal na cabra e na ovelha por ultra-sonografia. In: SANTOS, M.H.B. et al. **Diagnóstico de gestação na cabra e na ovelha.** São Paulo: Varela, 2004. p.117-136.

RIBEIRO, D.A.S. **Caprinocultura: criação racional de caprinos.** São Paulo: Nobel, 1997. 318p.

- SANTOS, M.H.B. et al. Utilização da ultrasonografia na sexagem de fetos da raça Anglo-nubiana pela identificação do tubérculo genital e da genitália externa. **Veterinária e Zootecnia**, v. 12, n.1/2, p.52-60, 2005a.
- SANTOS, M.H.B. et al. Identificação precoce do sexo fetal em pequenos ruminantes através da ultra-sonografia. **Acta Scientiae Veterinariae**, v.33, p.131-134, 2005b.
- SANTOS, M.H.B. et al. Sexing of Boer goat by transrectal ultrasonography. **Animal Reproduction**, v.3, n.3, p.371-375, 2006a.
- SANTOS, M.H.B. et al. Fetal sexing in Santa Inês ewes by ultrasonography. **Ciência Rural**, v.36, n.2, p.573-578, 2006b.
- SANTOS, M.H.B. et al. Diagnóstico precoce do sexo fetal nas espécies caprina e ovina através da ultra-sonografia. **Acta Scientiae Veterinariae**, v.33, p.59-64, 2006c.
- SANTOS, M.H.B. et al. Accuracy of early fetal sex determination by ultrasonic assessment in goats. **Research in Veterinary Science**, v.83, n.2, p.251-255, 2007a.
- SANTOS, M.H.B. et al. Determinação do período de migração do tubérculo genital na sexagem precoce de fetos ovinos das raças Damara, Santa Inês e ¾ Damara Santa Inês. **Ciência Animal Brasileira**, v.8, n.1, p.111-117, 2007b.
- SANTOS, M.H.B. et al. Determination of the genital tubercle migration in Morada Nova sheep fetuses by ultrasonography. **Reproduction in Domestic Animals**, v.42, p.214-217, 2007c.
- SANTOS, M.H.B. et al. Early fetal sexing of Saanen goats by use of transrectal ultrasonography to identify the genital tubercle and external genitalia. **American Journal of Veterinary Research**, v.68, n.5, p.561-564, 2007d.
- SANTOS, M.H.B. et al. Sexagem fetal pela ultrasonografia identificando-se o tubérculo genital ou a genitália externa de caprinos da raça Alpina Americana. **Ciência Animal Brasileira**, v.8, n.2, p.325-331, 2007e.
- SANTOS, M.H.B. et al. Sexing of Dorper sheep derived from natural mating and embryo transfer by ultrasonography. **Reproduction, Fertility and Development**, v.19, p.366-369, 2007f.
- SANTOS, M.H.B. et al. Sexagem precoce de fetos caprinos da raça Toggenburg pela ultra-sonografia transretal. **Medicina Veterinária**, v.1, n.1, p.48-54, 2007g.
- SANTOS, M.H.B. et al. Medidas do concepto utilizadas na prática ultra-sonográfica de pequenos ruminantes. In: _____. **Diagnóstico de gestação na cabra e na ovelha**. São Paulo: Varela, 2004a. p.137-148.
- SANTOS, M.H.B. et al. Diagnóstico de gestação por ultra-sonografia de tempo real. In: _____. **Diagnóstico de gestação na cabra e na ovelha**. São Paulo: Varela, 2004b. p.97-116.
- STROUD, B.K. Using ultrasonography to determine bovine fetal sex. **Veterinary Medicine**, v.91, p.663-672, 1996.
- VILELLA, L.C.V. et al. O material genético disponível no Brasil. In: CAMPOS, ACN (Ed.). **Do campus para o campo: tecnologias para produção de ovinos e caprinos**. Fortaleza, Brasil: Gráfica Nacional. 2005. p.215-225.
- WHITE, I.R. et al. Real-time ultrasonic scanning in the diagnosis of pregnancy and determination of fetal numbers in sheep. **Veterinary Record**, v.115, p.140-143, 1984.